

The DownPak Device: obturation with heat and vibration

Authors_Dr Stephen Cohen, Dr Louis H. Berman & Dr Gabriela Martin, USA

Successful endodontic treatment depends on a proper diagnosis, a favourable prognosis assessment and proper cleaning, disinfection, shaping, and obturation of the canals and their associated radicular spaces. As countless studies have demonstrated that it may not be possible to disinfect and clean all canal ramifications thoroughly, obturation makes it possible to seal the roots internally to prevent leakage coronally or from peri-radicular tissues.¹ Presently, there is no ideal obturation material. Gutta-percha remains the primary obturation material in use today, although other obturation filling materials have gained some recent attention, including Resilon (Pentron Clinical Technologies) and ProRoot MTA (DENTSPLY Tulsa Dental). All of these materials have some limitation in their ability to seal the main and accessory canals three-dimensionally. Nevertheless, it is important to obtain an homogenous mass

of obturation material that will conform well to the interior walls of the canals when plasticised. Gutta-percha and Resilon are the most suitable materials. Heated gutta-percha changes its crystalline form from a beta phase, which is relatively solid, to an alpha phase, in which it becomes a more plasticised and sticky material that adheres better to the canal walls.² In its alpha phase, gutta-percha can be compacted vertically and laterally, by mechanical or rotary instruments. Resilon, a polyester- and methacrylate-based resin obturation material, has good flow when warmed. One study concludes that Resilon bonds to etched canal walls when heated, which may provide a tighter seal of the canal system while also strengthening the root system.³

Several techniques have been used to facilitate the placement of gutta-percha, including cold and warm lateral compaction, warm vertical compaction, injectable systems, carrier-based obturation and thermomechanical compaction. All of these techniques require various degrees of clinical proficiency and, depending on the canal system that is to be obturated, certain techniques may be more appropriate than others. For example, when a tooth has a large internal resorption defect in the canal, cold lateral compaction may not adequately fill all of the canal space, whereas vertically compacting or injecting warm gutta-percha may provide a more 3-D obturation. Considering the multitude of canal ramifications in any given tooth, it may be impossible to fill these spaces three-dimensionally unless the gutta-percha is heated. *In vitro* studies have demonstrated that cold lateral compaction of gutta-percha is approximately 25 per cent less dense than warm lateral compaction; additionally, it has been shown that gutta-percha fills significantly more canal space when warm vertical compaction is used.⁴⁻⁶ Even after heating and compacting gutta-percha or Resilon into a canal system, there still may be voids in the obturation. To min-

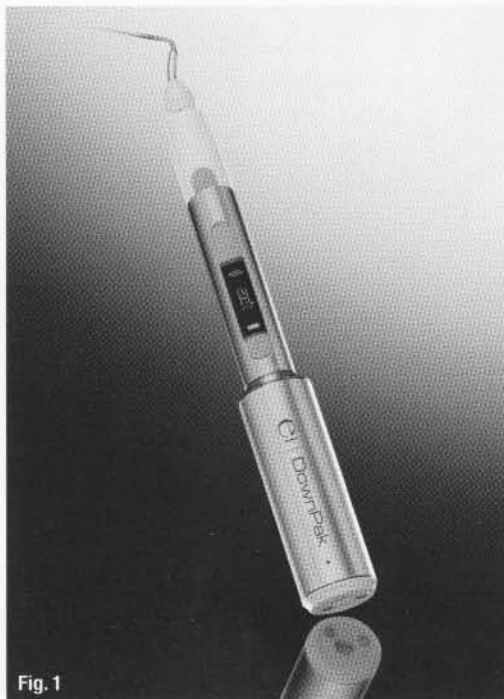
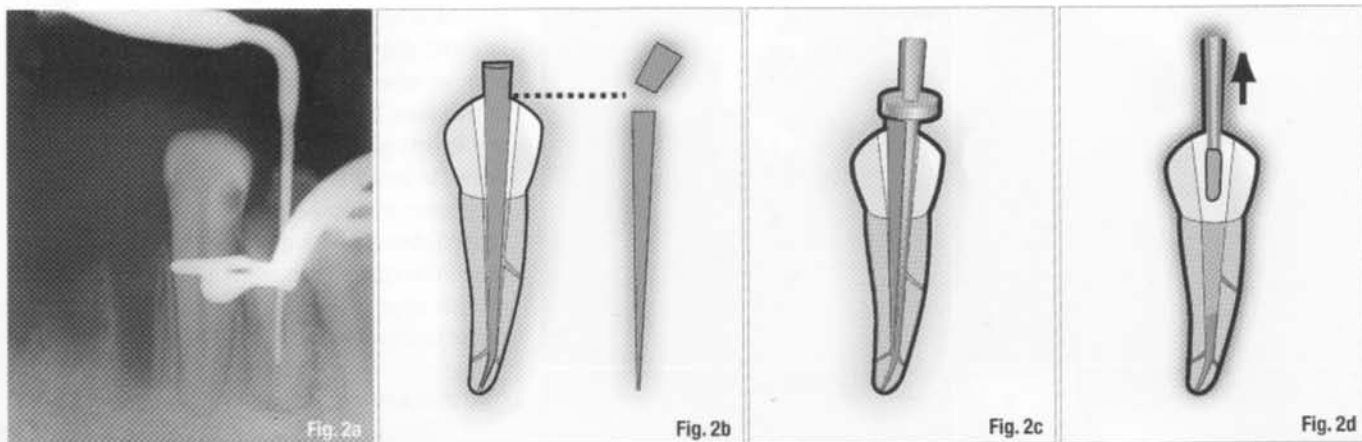


Fig. 1

Fig. 1_The DownPak is a self-contained device that transfers heat and vibration to a spreader or plugger tip. All of the controls are easily accessible on the handle.



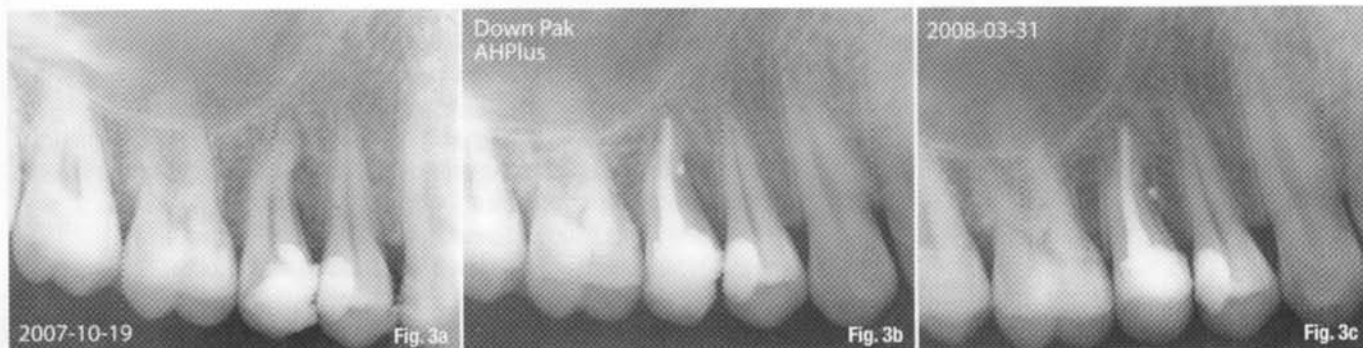
imise this problem, Dr Howard Martin developed a self-contained electronically heated spreader for warming and laterally compacting gutta-percha (Endotec, Medidenta International). This device significantly enhanced the compaction of gutta-percha.⁷ A 1993 study found that the Endotec device increased the density of the obturation by approximately 15 percent.⁸ Although this obturation device is no longer commercially available, it demonstrated that electrically induced heat on a spreader or plugger tip is an efficient way of delivering heat to gutta-percha, producing a denser obturation as a result. Subsequently designed obturation heating systems, the Touch 'n Heat (SybronEndo) and the System B (SybronEndo), expanded on this concept and were found to be successful for creating a more homogenous obturation of gutta-percha.⁹ The EndoTwin (MDCL) is another such device that has been used throughout Europe for many years. Like the Endotec, the EndoTwin is a hand-held, self-contained, heat-carrying instrument with spreader and plugger tips. Sonic vibration was also incorporated into this device to augment the compaction and obturation effectiveness of EndoTwin's heated tips. Several studies have reported that by simultaneously combining the efficacy of heating the obturating material with sonic vibration to help the plasticised gutta-percha flow, the average percentage of gutta-percha in the canal space could increase significantly, especially in the more narrowly tapered canals.¹⁰⁻¹² In early 2007, efforts to improve

and refine the EndoTwin led to the introduction of the DownPak (Hu-Friedy). The DownPak enables the clinician to employ variable temperature settings and to turn the vibration feature on or off as desired.¹³ The variable temperature settings become useful when different obturation materials are used. For example, Resilon softens at a lower temperature than gutta-percha. The DownPak is cordless and lightweight, with an ergonomically balanced hand-held grasp; all of the switches and adjustments are easily accessible on the handle (Fig. 1).

Technique

The use of the DownPak is similar to a combined vertical and lateral compaction of gutta-percha, so the clinician familiar with these techniques should find the device very user-friendly. First, the appropriate DownPak tip is selected so that it reaches a depth in the canal that is 3 to 5 mm from the apical terminus. A silicone stop can be adjusted on the tip as a reference point for this measurement (Fig. 2a). Next, the canal walls are coated with sealer and a master gutta-percha (or Resilon) cone is placed in the canal to working length. Using the tip of the heated DownPak, excess coronal gutta-percha is removed to the level of the orifice (Fig. 2b). With a sustained push, the DownPak tip is introduced into the canal with the heat and vibration modes activated. The tip is then extended down the canal space to the predetermined binding point, 3 to 5 mm from

Fig. 2a The appropriate DownPak tip is selected to extend 3 to 5 mm from the apical terminus. A silicone stop on the tip is adjusted as a reference point.
Fig. 2b Canal walls are coated with sealer and a master gutta-percha (or Resilon) cone is placed in the canal to working length. Using the tip of the heated DownPak, excess coronal gutta-percha is removed to the level of the orifice.
Fig. 2c The DownPak tip is introduced into the canal to the predetermined binding point with the heat and vibration modes activated for two to four seconds. The tip is rotated rapidly 180 degrees clockwise/counterclockwise two or three times and heated for two seconds.
Fig. 2d The tip is removed quickly along with any excess gutta-percha. Remaining voids are sealed coronally with additional accessory cones by applying vertical compaction as described above.
Fig. 3a Pre-op radiograph of maxillary right second pre-molar: note apical dilacerations and peri-radicular bone loss.
Fig. 3b Immediately after obturation: note the lack of voids and the lateral canal filled on the mesial.
Fig. 3c Five months post-endodontic treatment: note the re-mineralisation in the area of the peri-radicular bone.



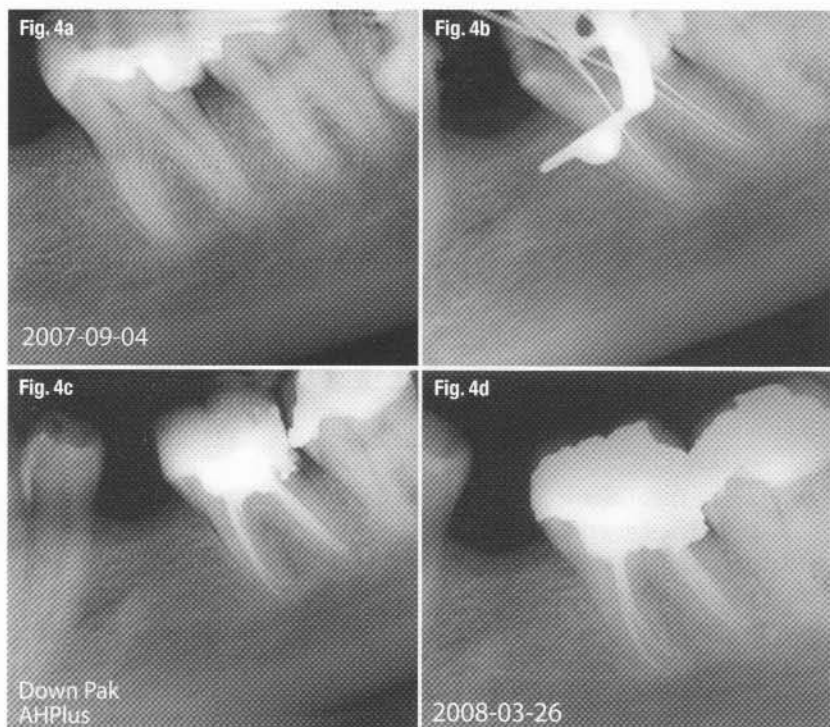


Fig. 4a Pre-op radiograph of mandibular left first molar.
Fig. 4b Working length radiograph depicting four canals, each with a separate apical terminus.
Fig. 4c Immediately after obturation.
Fig. 4d Six months post-endodontic treatment: note favourable peri-radicular bone healing.

the apical terminus (Fig. 2c). The tip is rotated rapidly 180 degrees clockwise/counterclockwise two or three times and heated for two to four seconds; at this time, the tip is removed quickly along with any excess gutta-percha (Fig. 2d). Any remaining voids can be sealed coronally with additional accessory cones by applying vertical compaction as described above. Although radiographs are only 2-D, the clinical cases depicted in Figures 3 and 4 provide an indication of the clinical effectiveness of obturating canals using the DownPak.

Summary

The literature and this article have documented the benefits to patients when clinicians employ plasticised gutta-percha and vertical compaction combined with vibration. The advent of cordless devices like the DownPak makes it easier for the clinician to provide a 3-D obturation more effectively.

Editorial note: A complete list of references is available from the publisher.

about the authors

roots



Dr Stephen Cohen is the senior editor of all nine editions of *Pathways of the Pulp*. He is a diplomate of the American Board of Endodontics and has held leadership positions in many of the major professional and academic organisations in endodontics. Dr Cohen is Adjunct Professor of Endodontics in the Arthur A. Dugoni School of Dentistry at the University of the Pacific in San Francisco and Professor of Endodontics in the Department of Preventive and Restorative Dental Sciences at the University of California, San Francisco. He also serves on the advisory board of Hu-Friedy Co. Dr Cohen can be contacted at scohen@unionsquareendo.com.



Dr Louis H. Berman is a former clinical instructor and guest lecturer at the Albert Einstein Medical Center and former Assistant Professor of Endodontics at the University of Maryland School of Dentistry. He is past president (1999–2000) of the Maryland State Association of Endodontists and a member of the *Journal of Endodontics* Scientific Advisory Panel. Dr Berman is the senior author for the chapter on diagnosis in the ninth edition of *Pathways of the Pulp*. He is also the senior editor and contributing author of the comprehensive textbook *A Clinical Guide to Dental Traumatology*, published by Mosby in 2006. A board-certified endodontist, he has been in full-time private practice in Annapolis in Maryland for the past 25 years. Dr Berman can be contacted at Berman@AnnapolisEndodontics.com.



Dr Gabriela Martin is Professor of Endodontics at the School of Dentistry at the National University of Cordoba in Argentina. She obtained her Certification in Endodontics in 2000 through the Argentine Society of Endodontics and is an active member of the Argentine Association of Dentistry. She is a voter member of the Association of Endodontics of Cordoba, Argentina and teaches hands-on courses at the Dentistry Association of Cordoba. Her dentistry work is focused on endodontics, and she has been in private practice in Cordoba since 1992. Dr Martin can be contacted at ggmartin@hotmail.com.